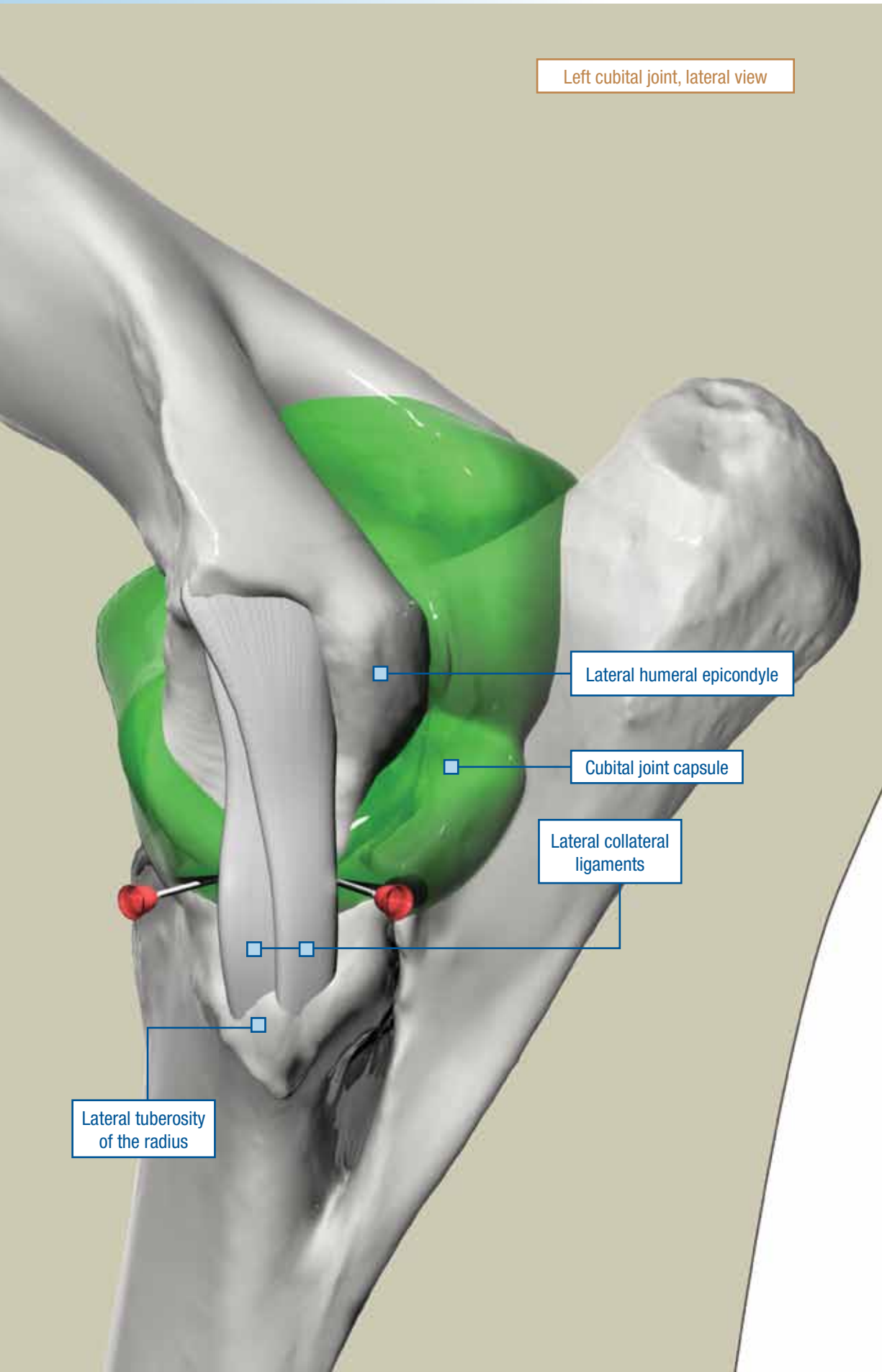


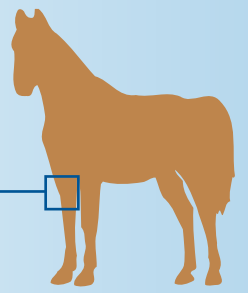
CUBITAL JOINT (ELBOW)

LATERAL APPROACH

Left cubital joint, lateral view



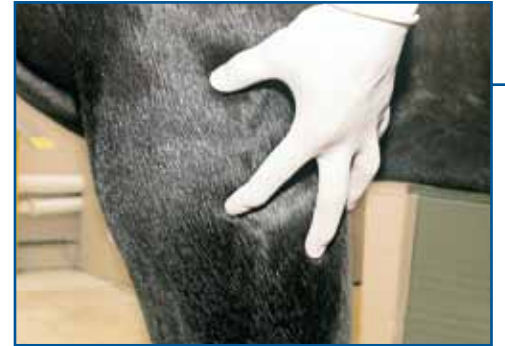Needle: 1.5 in. (3.8 cm), 20 ga
 Volume: 20 to 30 mL
 Degree of difficulty: 2/3



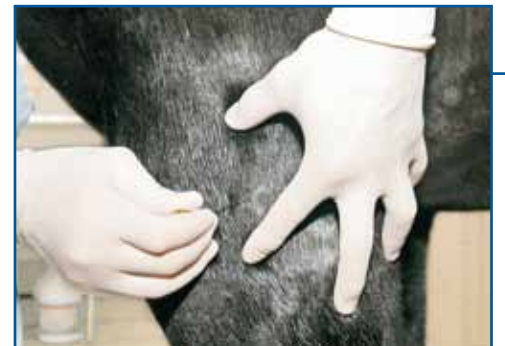The **cubital joint** (elbow), or combined humero-radial, humeroulnar, and radioulnar joints, is not usually a source of lameness and, therefore, is rarely injected. With careful palpation, it is not a difficult joint to inject. The joint capsule of the elbow has cranial and caudal pouches. The palpable landmarks of the cranial pouch are the lateral humeral epicondyle, the lateral tuberosity of the radius, and the lateral collateral ligament of the elbow.

Using a lateral approach, insert the needle either cranial or caudal to the palpable edge of the lateral collateral ligament. The joint margin is approximately two-thirds of the distance, measured distally, from the lateral humeral epicondyle to the radial tuberosity. The depth of penetration is usually 1 inch (2.5 cm). In some cases, inadvertent deposition of local anesthetic solution outside the elbow joint may result in anesthesia of the radial nerve. For this reason we prefer to use lidocaine for this block because it provides a shorter duration of anesthesia.

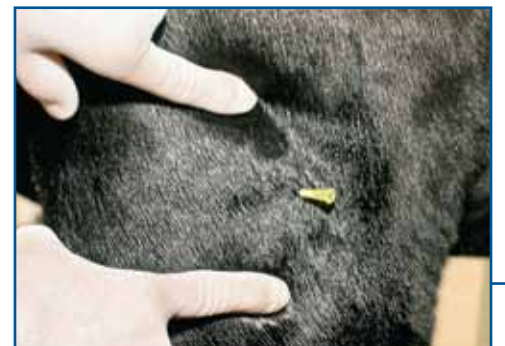The elbow joint communicates with the bursa of the ulnaris lateralis muscle in about one-third of horses.⁵⁰



Palpate the lateral humeral epicondyle and the lateral tuberosity of the radius. *Note: The left forelimb is being palpated.*



Insert the needle cranial to the palpable edge of the lateral collateral ligament of the elbow. *Note: Needle is in the left forelimb.*

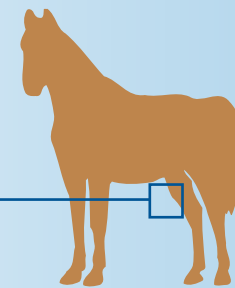
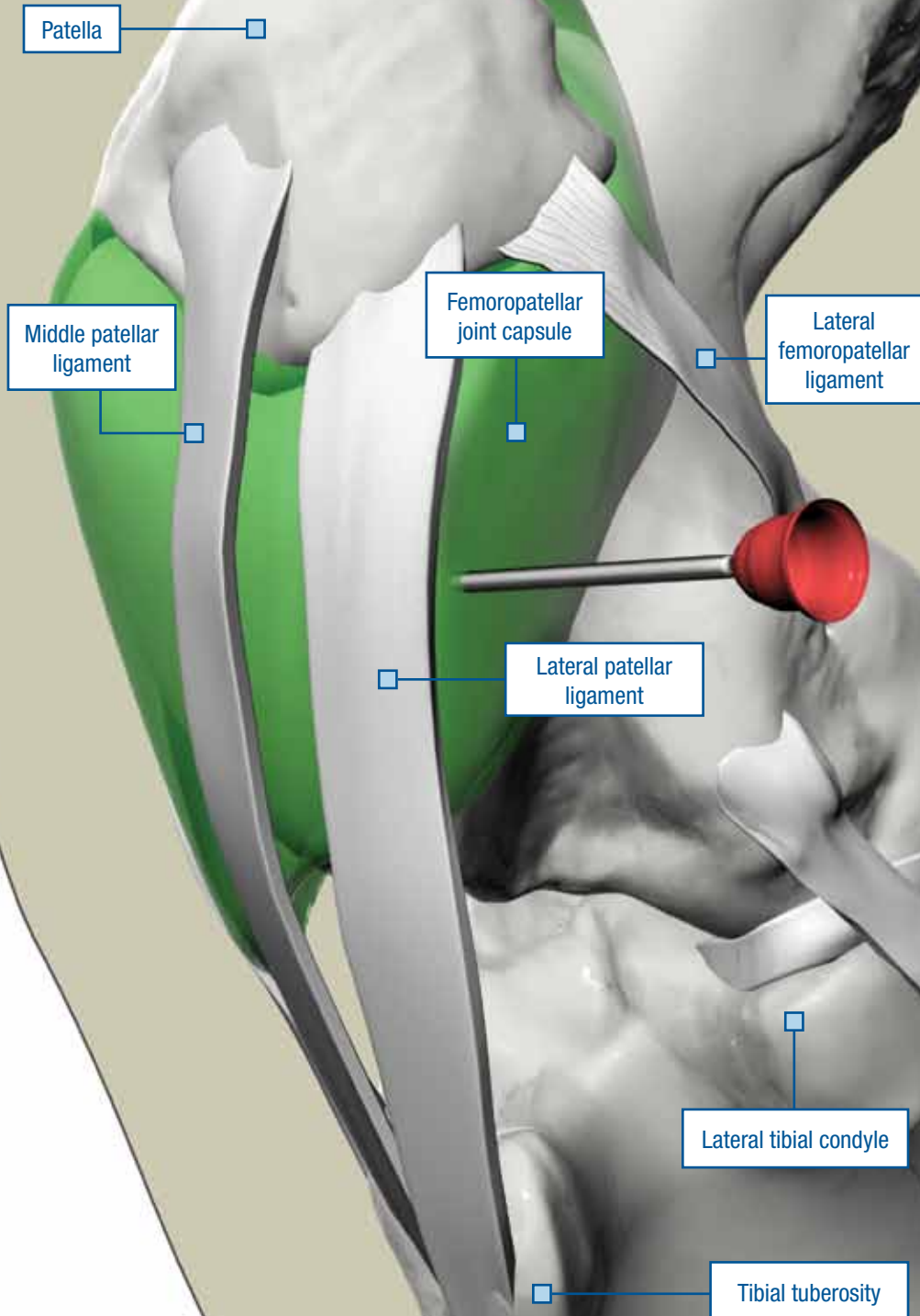


Alternatively, the needle can be inserted caudal to the palpable edge of the lateral collateral ligament of the elbow. *Note: Needle is in the left forelimb.*

FEMOROPATELLAR JOINT

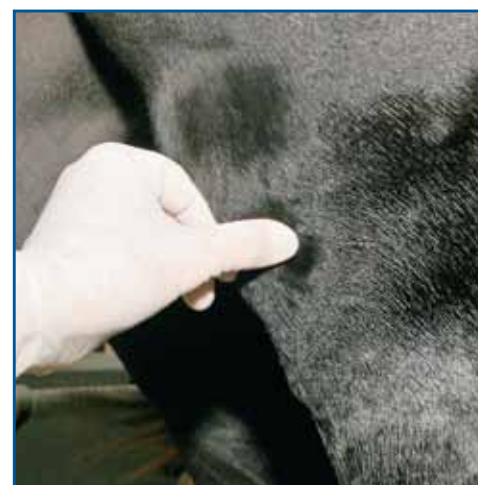LATERAL APPROACH

Left stifle, craniolateral view

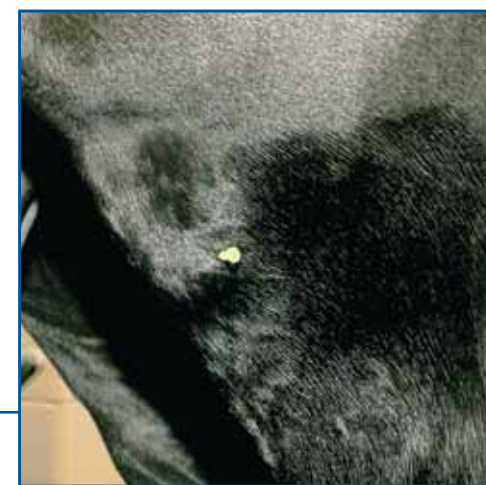

Needle: 1.5 in. (3.8 cm), 18 to 20 ga
 Volume: 20+ mL
 Degree of difficulty: 2/3

An alternate approach to the **femoropatellar joint**, described by Hendrickson and Nixon,⁶⁷ is to insert the needle into the lateral cul-de-sac of the joint. Direct a 1.5-inch (3.8-cm), 18- to 20-gauge needle perpendicular to the long axis of the limb, approximately 2 inches (5 cm) above the palpable lateral edge of the lateral tibial condyle, just behind the caudal edge of the palpable lateral patellar ligament. Insert the needle until bone is contacted, and then slightly withdraw it. Synovial fluid can usually be aspirated.

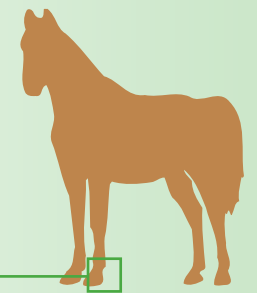


Palpate the lateral edge of the lateral tibial condyle. *Note: The left hindlimb is being palpated.*



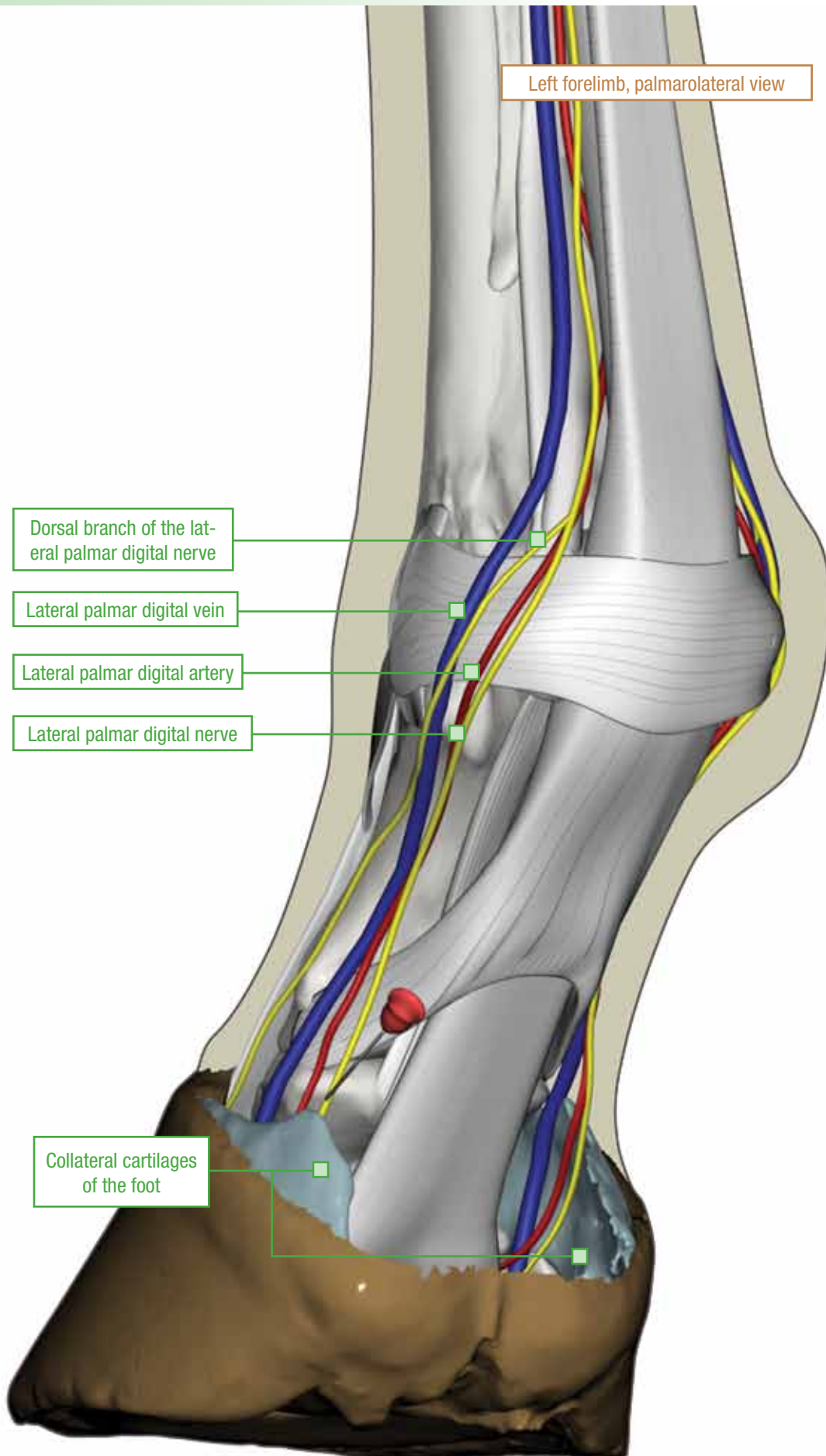
Insert the needle perpendicular to the long axis of the limb, about 2 inches (5 cm) above the lateral edge of the lateral tibial condyle and just behind the caudal edge of the palpable lateral patellar ligament, until bone is contacted; then slightly withdraw the needle. *Note: Needle is in the left hindlimb.*

PALMER DIGITAL NERVE BLOCK



Needle: 5/8 in. (1.6 cm), 25 ga
Volume: 1.5 mL at each site

Left forelimb, palmarolateral view

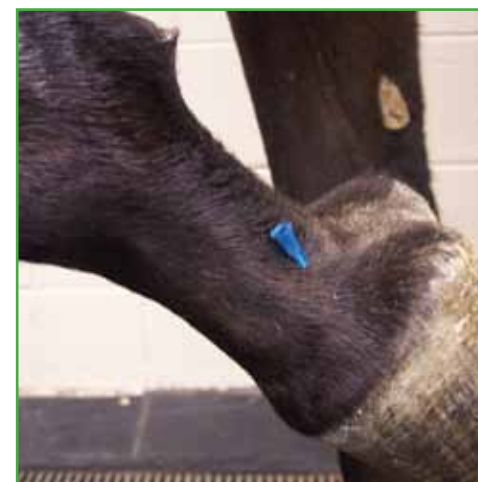

With the limb held, the **palmar digital nerve block** is performed by inserting the needle directly over the palmar aspect of the palpable neurovascular bundle about 0.4 inch (1 cm) above the collateral cartilage of the foot. Insertion of a needle at this site causes local anesthetic solution to be deposited at or slightly below the level of the caudal border of the proximal interphalangeal (pastern) joint because the height of the collateral cartilage of the foot in relation to the level of the caudal border of the pastern joint is probably similar for most horses.⁹

Insert a 5/8-inch (1.6-cm), 25-gauge needle in a distal direction, and deposit local anesthetic solution near the junction of the nerve and the collateral cartilage of the foot. By injecting local anesthetic solution as the needle is withdrawn, the solution is deposited in different tissue planes and is less likely to be administered intravascularly in either the digital artery or vein located adjacent to the nerve. Injecting as the needle is withdrawn, however, causes more proximal deposition of local anesthetic solution, which increases the likelihood of anesthetizing branches of the digital nerve that supply the pastern joint.

The palmar digital nerve block is sometimes referred to as the *heel block*, but anesthesia of the palmar or plantar digital nerves anesthetizes much more than the heel region of the foot. When local anesthetic solution is deposited at the recommended site (i.e., the junction of the nerve and the collateral cartilage of the foot), the following structures are desensitized: the entire sole,¹⁰ the navicular apparatus and soft tissues of the heel,¹¹ the entire distal interphalangeal joint (coffin joint) of the forelimb,¹² and often, the digital portion of the deep digital flexor tendon.¹³ For some horses, the pastern joint is at least partially desensitized.⁹ The likelihood of desensitizing the pastern joint increases as the volume of local anesthetic solution increases and as the solution is deposited more proximally.

Resolution of lameness or loss of skin sensation at the coronary band in the palmar portion of the foot (i.e., the heel) indicates that the palmar digital nerve block was successful.



With the limb held, insert the needle directly over the palmar aspect of the palpable neurovascular bundle, about 0.4 inch (1 cm) above the collateral cartilage of the foot.
Note: Needle is in the left forelimb.